

Research Journal of Pharmaceutical, Biological and Chemical Sciences

Torsion of Ovarian Cyst in First Trimester of Pregnancy: A Case Report.

KS Priyadharisini*, and T Suganya.

Sree Balaji Medical College and Hospital, Chennai - 600044 Tamil Nadu, India.

ABSTRACT

In this case we report a 22 year-old primi gravida with 10 weeks presenting with torsion of the ovarian cyst. She presented to the antenatal clinic with acute pain abdomen. She was diagnosed to have torsion of ovarian cyst during pregnancy and a cystectomy was carried out. Her histopathology report showed a benign serous cyst adenoma. Her pregnancy was followed up till term. She delivered a healthy male baby at term. Although the safety of antepartum surgical intervention has been accepted, abdominal surgery carries some risks to a pregnant woman and fetus, and so the choice of management depends on weighing the risks based on characterization of the adnexal mass and gestational age.

Keywords: Partial rotation, Bicornuate uterus, Cystectomy, Rupture, Solid components.

**Corresponding author*

INTRODUCTION

Torsion of ovary is the total or partial rotation of the adnexa around its vascular axis or pedicle. Moderate size, free mobility and long pedicle are predisposing factors. The exact etiology is not known. Most commonly seen are dermoid and serous cystadenomas. Complete torsion causes venous and lymphatic blockage leading to stasis and venous congestion, haemorrhage and necrosis. The cyst becomes tense and may rupture. Patient presents with acute severe pain abdomen and pelvic examination reveals a tender cystic mass separate from the uterus. The risk of ovarian torsion rises by 5 times during pregnancy. Incidence is 5 per 10,000 pregnancies. Torsion of ovarian tumors occurred predominantly in the reproductive age group. The majority of the cases presented in pregnant (22.7%) than in non-pregnant women (6.1%).

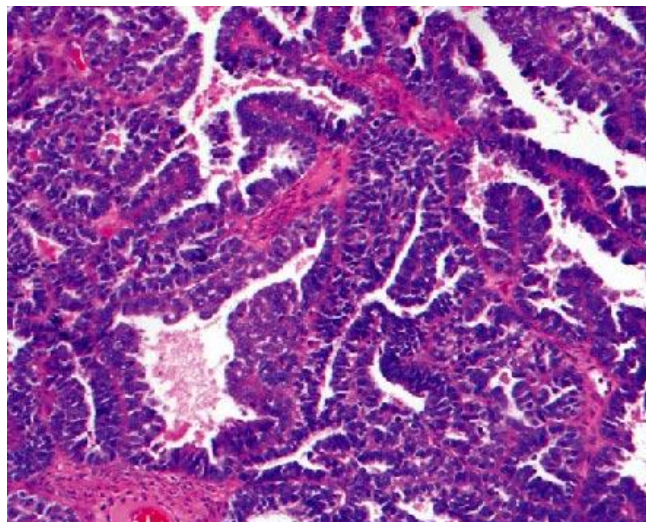
Case Report

A 22 year old primi gravida presented to the antenatal clinic with 2 and 1/2 months amenorrhoea and pain abdomen and 3 episodes of vomiting, since one day. Her menstrual cycles were regular. She described the pain as sharp non-radiating type of pain in the right iliac fossa with sudden onset, with no relieving factors. She gave no history of spotting, discharge or fever. Her bowel and bladder habits were normal. She conceived spontaneously. No significant past medical and surgical history noted.

On examination, patient was conscious, coherent with pulse rate 82/min, blood pressure 110/70 mm of hg, temperature normal, cardiovascular and respiratory systems normal. Abdomen examination revealed guarding all over the lower abdomen with Right iliac fossa and suprapubic region tenderness.

On Speculum examination, mild mucoid discharge present. On vaginal examination, cervix pointing upwards, Uterus retroverted about 10 weeks size, Right fornix fullness present, Mass measures about 6 x 7 cms, right fornix tenderness present. All her blood and urine investigations were within normal limits. Ultrasonography revealed a 7 x 5 cm single anechoic cystic lesion in right iliac fossa with single thin septation and no solid components. It also showed a single live intrauterine fetus of 9 – 10 weeks. Evidence of free fluid in the abdomen. With the provisional diagnosis of twisted ovarian cyst, emergency laparotomy was done under regional anaesthesia.

On Laparotomy, a 7 x 5 cm right ovarian cyst was found to be twisted around its pedicle by 3 rotations. After untwisting, cystectomy was done. The cyst was sent for histopathological examination. Patient recovered with an uneventful postoperative period and was discharged on 10th post operative day. Her histopathology report showed benign serous cystadenoma of the ovary. She was followed up, her pregnancy continued uneventfully and she delivered an alive Male baby of birth weight 2.75 kg at term gestation by caesarean section.



Picture showing Benign serous cyst adenoma of the ovary.

DISCUSSION

The commonest type of ovarian tumours encountered in pregnancy are cystic teratoma, paraovarian cyst, serous cystadenoma, corpus luteal cysts etc. Serouscystadenomas are thin walled, translucent cysts usually unilocular, varying between 20- 30 cms in size. They are often unilateral, rarely bilateral. 10-15% of them are borderline malignant while 20 - 40% are malignant.

Differential diagnosis includes: uterine fibroids, non pregnant horn of bicornuate uterus, appendiceal abscess, diverticular abscess, ectopic pregnancy and retroverted gravid uterus. Complications of the cysts associated with pregnancy are torsion of the cyst, rupture, infection, malignancy, impaction of cyst in pelvis causing retention of urine, obstructed labour and malpresentations of the fetus, Tumor rupture, or obstruction of labor.

Other studies have recommended the principle of observation, finding that most ovarian Masses can either remain uneventful or resolve throughout pregnancy. Its most common cause in pregnancy is a corpus luteum cyst, which usually regresses spontaneously by the second trimester. Ovarian torsion, therefore, occurs most frequently in the first trimester, occasionally in the second trimester, and rarely in the third trimester.

MANAGEMENT

Cysts less than 6 centimetres and appearing benign on ultrasound are generally treated conservatively as they may undergo spontaneous regression. Corpus luteal cysts regress by 12 to 16 weeks. Cysts more than 10 centimetres in size are usually removed due to increased risk of malignancy, rupture or torsion.

Management of cysts between 5 to 10 centimetres is controversial. If the cysts contain septae, nodules, papillary excrescences or solid components then surgical intervention is recommended. Those with simple cystic appearance may be managed expectantly with serial ultrasound surveillance. However they may require emergency exploratory laparotomy for rupture, torsion or infarction in as many as 50% cases.

With the advent of imaging techniques like MRI and transvaginal colour Doppler, the expectant management has become much more common. Ovarian tumour or Cyst can be easily removed till 28 wks of gestation thereafter it is difficult for surgery and may precipitate preterm labour. Ovarian cyst which ruptures, or undergoes torsion or if it shows evidence of malignancy, requires immediate surgical intervention, respective of the period of gestation. A simple cystectomy can be performed in the absence of malignant features. Previously untwisting of the pedicle was avoided to prevent emboli from entering peripheral circulation but recently, re-establishing ovarian circulation by untwisting, has shown to result in viable ovarian tissue with no systemic complications [1-7].

CONCLUSION

Ovarian torsion is relatively common in the first trimester of pregnancy. Diagnosis is made on the basis of the characteristic clinical presentation and with ultrasound evidence of an enlarged adnexal mass. Treatment options are limited to surgery, either by laparoscopy or laparotomy.

REFERENCES

- [1] Blumenfeld Z. et al. Transvaginal Sonographic assessment of early embryological development. In T. Tritsch and S. Rolten (eds) Transvaginal Sonography London. Heinemann 2002 Pp 87-108.
- [2] Yen CF, Lin SL, Murk W, Wang CJ, Lee CL, Soong YK and Arici. Fertil Steril 2009;91:1895-902.
- [3] Duic Z, Kukura V, Ciglar S, et al. Eur J Gynaecol Oncol 2002;23:133-134.
- [4] Whitecar MP, Turner S and Higby MK. Am J Obstet Gynecol 1999;181:19-24.
- [5] Schmeler KM, Mayo-smith WW, Peipert JF, Weitzen S, Manuel MD and Gordinier. Obstet Gynecol 2005;105:1098-103.
- [6] Lee CH, Raman S, Sivanesaratnam V 1989: Torsion of ovarian tumors: a clinicopathological study. Int J Gynaecol Obstet 1989;28:21-25.
- [7] Poornima R Ranka et al. Ovarian dermoid or chronic ectopic a diagnostic dilemma. 1999-4104.